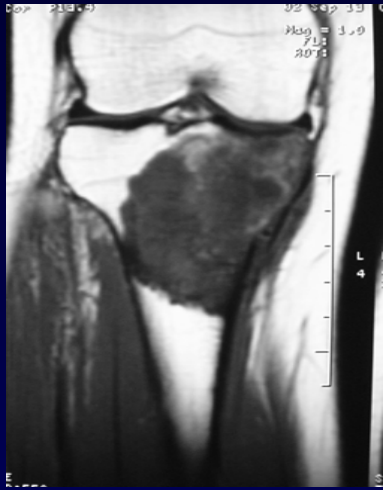



大型骨欠損部への応用: 脛骨近位骨肉腫 (19才、女)



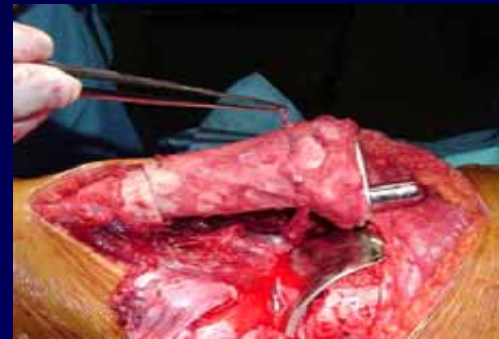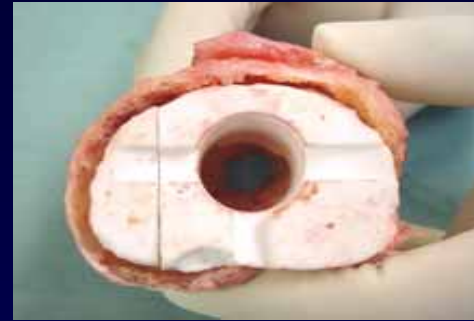

脛骨骨肉腫



切削器へのデータ送信



人工骨の作成



前脛骨動脈の導入

