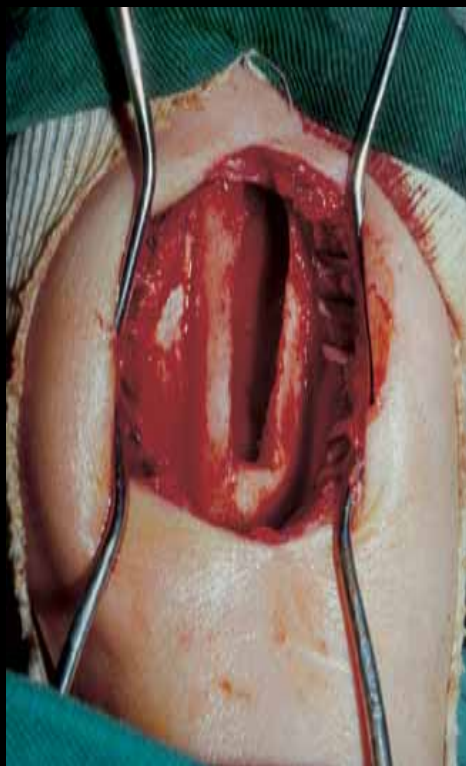
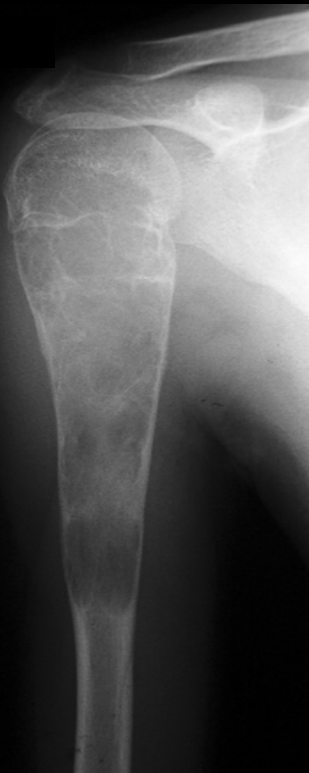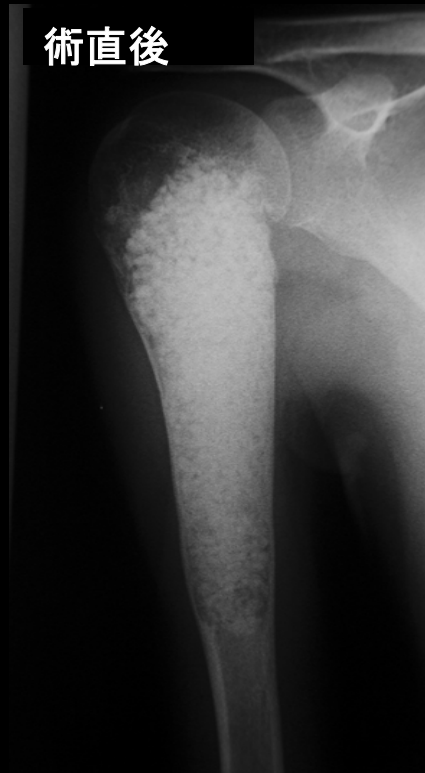


14才、男子、上腕骨骨嚢腫

術前



術直後



3ヶ月

