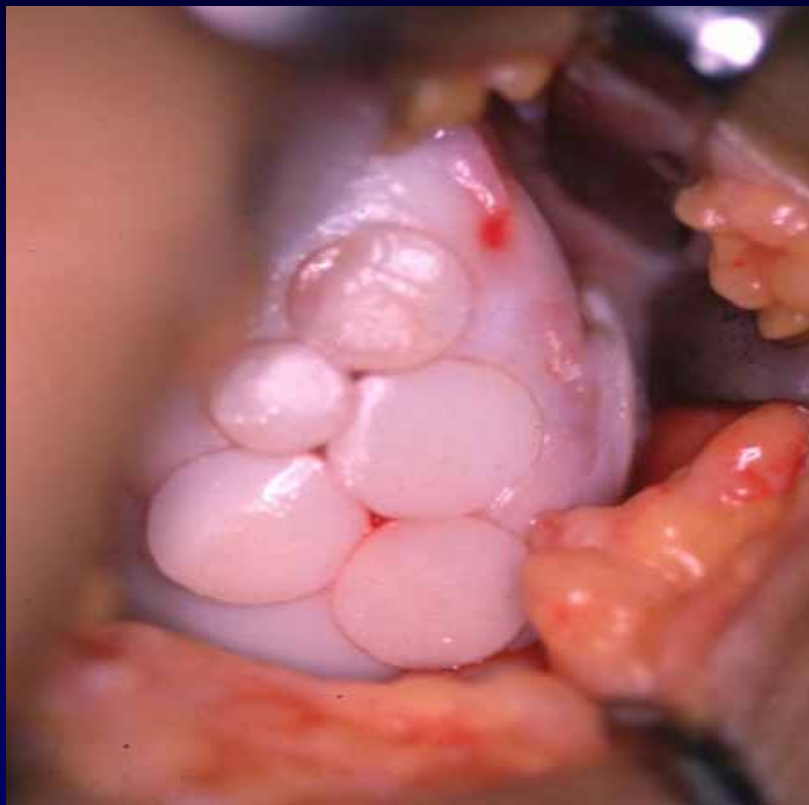
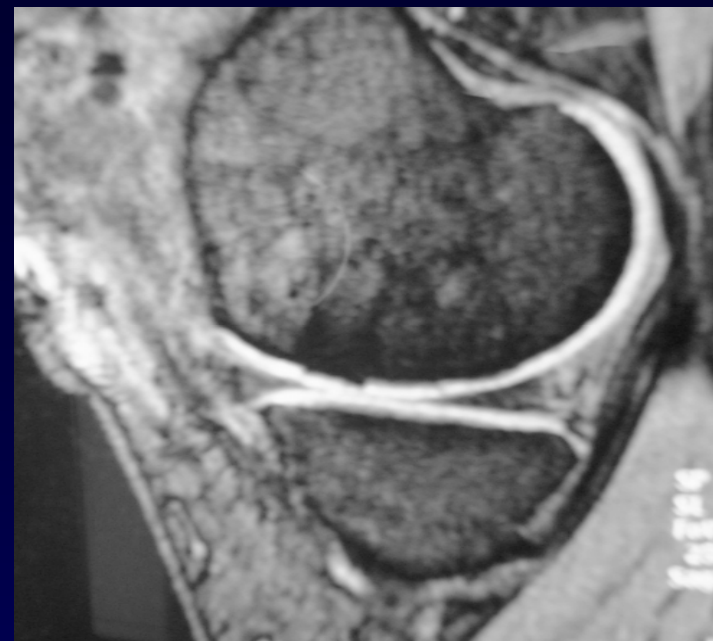


26才、女性、スポーツ障害

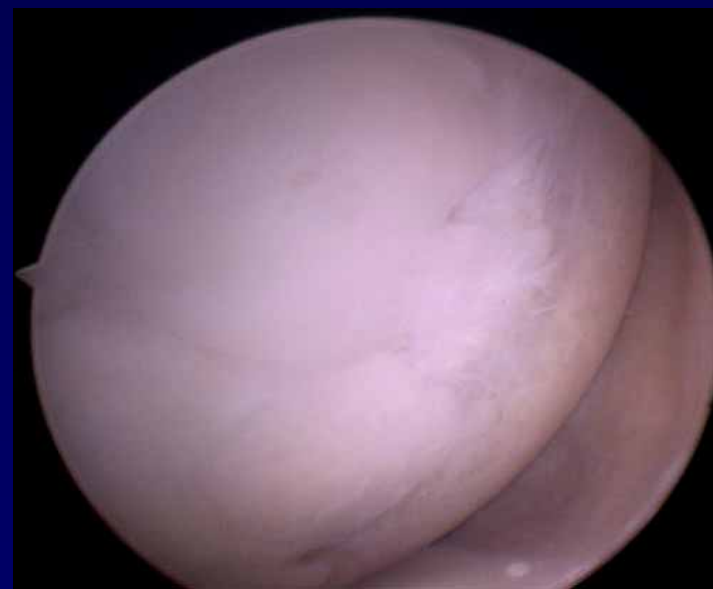

術中

MRI



関節鏡



術後12ヶ月